

CASE REPORT

Open Access



# Sibling cases of gross hematuria and newly diagnosed IgA nephropathy following SARS-CoV-2 vaccination

Yuri Uchiyama<sup>1†</sup>, Hiroataka Fukasawa<sup>1\*†</sup> , Yuri Ishino<sup>1</sup>, Daisuke Nakagami<sup>1</sup>, Mai Kaneko<sup>1</sup>, Hideo Yasuda<sup>2</sup> and Ryuichi Furuya<sup>1</sup>

## Abstract

**Background:** Severe acute respiratory syndrome coronavirus 2 (SARS-CoV-2) vaccination has become a major part of the strategy to reduce Coronavirus disease 2019 (COVID-19) numbers worldwide. To date, vaccinations based on several mechanisms have been used clinically, although relapse of existent glomerulonephritis presenting as gross hematuria, and occurrence of *de novo* glomerulonephritis have been reported.

**Case presentation:** We report the first sibling cases newly diagnosed as immunoglobulin A (IgA) nephropathy after the second dose of SARS-CoV-2 vaccination. 15- and 18-year-old men presented with gross hematuria following the second dose of SARS-CoV-2 vaccine (Pfizer, BNT162b2) received on the same day. Pathological findings of each kidney biopsy specimen were consistent with IgA nephropathy. Gross hematuria in both cases spontaneously recovered within several days.

**Conclusions:** These cases indicate that SARS-CoV-2 vaccination might trigger *de novo* IgA nephropathy or stimulate its relapse, and also highlight the necessity of understanding the immunological responses to the novel mRNA vaccines in patients with kidney diseases.

**Keywords:** COVID-19, Gross hematuria, IgA nephropathy, SARS-CoV-2 vaccination, Sibling

## Background

Coronavirus disease 2019 (COVID-19) pandemic is a public health emergency all over the world and its effective control is expected by the execution of a global vaccination strategy [1]. Recently, several types of vaccines against severe acute respiratory syndrome coronavirus 2 (SARS-CoV-2) developed and progressively used worldwide [2–5].

On the other hand, several studies have reported the appearance of gross hematuria following messenger ribonucleic acid (mRNA)-based SARS-CoV-2 vaccination in patients with glomerulonephritis or in patients developing *de novo* glomerulonephritis post vaccination, especially those with immunoglobulin A (IgA) nephropathy [6–14].

In this manuscript, we report the first sibling cases of newly diagnosed IgA nephropathy who developed gross hematuria following the second dose of SARS-CoV-2 vaccination.

<sup>†</sup>Yuri Uchiyama and Hiroataka Fukasawa have contributed equally to this manuscript as co-first authors

\*Correspondence: hfukasawaucsd@gmail.com

<sup>1</sup> Renal Division, Department of Internal Medicine, Iwata City Hospital, 512-3 Ohkubo, Iwata, Shizuoka 438-8550, Japan

Full list of author information is available at the end of the article



## Case presentation

### Patient 1

A 15-year-old Japanese man with a 6-months history of microscopic hematuria was referred to our hospital due to gross hematuria 1 day after receiving the second dose of SARS-CoV-2 vaccine (Pfizer, BNT162b2). He also had fever and myalgia. He had no prior history of COVID-19 infection, nor gross hematuria after any other infections. He had no family medical history of kidney diseases.

Physical examination on admission revealed body temperature of 37.7 °C, pulse rate of 72 beats/min, blood pressure of 115/64 mmHg and no costovertebral angle tenderness.

Laboratory findings revealed serum creatinine of 0.97 mg/dL, estimated glomerular filtration rate (eGFR) of 92 mL/min/1.73 m<sup>2</sup>, and urinalysis revealed numerous red blood cells and moderate proteinuria Table 1. There was no morphological abnormality of his kidneys in the imaging of computed tomography scan.

The kidney biopsy was performed 7 days after the onset of gross hematuria. Among 21 glomeruli sampled, there were no globally sclerotic glomeruli. All glomeruli showed diffuse and mild mesangial expansion and hypercellularity, and 1 of which had a cellular crescent formation. There was approximately 10-20% tubulointerstitial fibrosis of the cortex and no arterio- and arteriolosclerosis.

**Table 1** Clinical characteristics and laboratory findings on initial presentation

Variables	Patient 1	Patient 2
Age, years	15	18
Gender	Male	Male
Duration to hematuria after vaccination	1 day	2 days
Body mass index, kg/m <sup>2</sup>	22.0	18.2
Hemoglobin, g/dL	13.8	15.7
Albumin, g/dL	5.3	5.2
LDL cholesterol, mg/dL	51	111
Blood urea nitrogen, mg/dL	10	11
Serum creatinine, mg/dL	0.97	0.82
eGFR, mL/min/1.73m <sup>2</sup>	92	105
Serum sodium, mEq/L	139	139
Serum potassium, mEq/L	4.0	4.2
CRP, mg/dL	0.55	0.52
Serum HCO <sub>3</sub> <sup>-</sup> , mEq/L	28.4	25.9
Urinary protein, (-) - (3+)	3+	1+
Urinary protein, g/gCreatinine	0.9	0.4
Urinary occult blood, (-) - (3+)	3+	3+
Urinary β2-microglobulin, µg/L	125	72
Urinary NAG, IU/L	1.8	3.0

**Abbreviations:** CRP C-reactive protein, eGFR estimated glomerular filtration rate, HCO<sub>3</sub><sup>-</sup> bicarbonate, LDL low-density lipoprotein, NAG N-acetyl-glucosaminidase

Immunofluorescence revealed global mesangial staining of IgG (1+), IgA (2+), IgM (±), C3 (1+), C4 (-) C1q (-) and fibrinogen (±). Ultrastructural examination revealed electron dense deposits in the mesangium and mild podocyte foot process effacement (Fig. 1). Pathological features were consistent with IgA nephropathy and the Oxford MEST-C classification was M1E0S0TOC1 [15]. His gross hematuria spontaneously resolved within 6 days without any treatment, although his microscopic hematuria and proteinuria persisted after that.

### Patient 2

An 18-year-old Japanese man with a 3-years history of microscopic hematuria was referred to our hospital due to gross hematuria 2 days after receiving the second dose of the SARS-CoV-2 vaccine (Pfizer, BNT162b2). In fact, he was the brother of patient 1 and had received the vaccination on the same day. He also had fever and general malaise. He had no prior history of COVID-19 infection, nor gross hematuria after any other infections. He had no family medical history of kidney diseases.

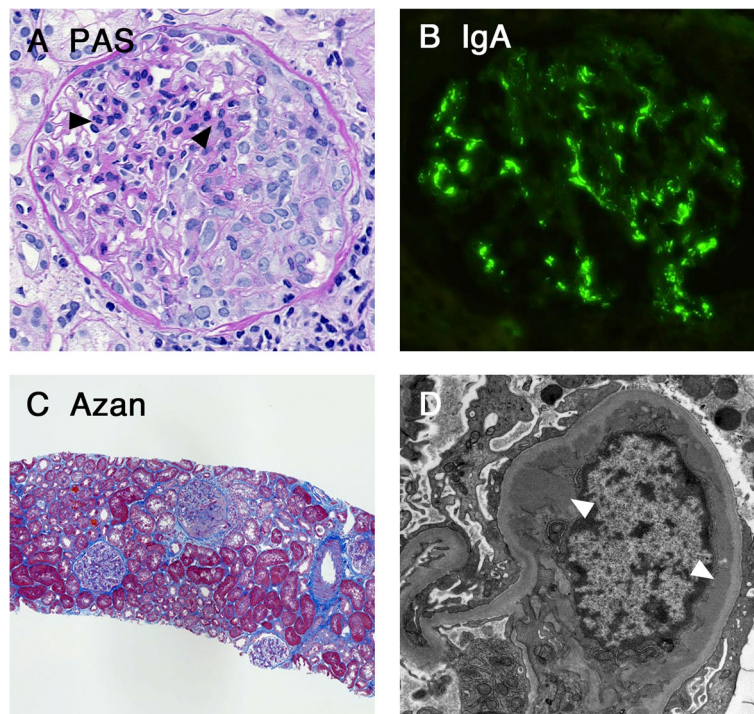
Physical examination on admission revealed body temperature of 38.6 °C, pulse rate of 83 beats/min, blood pressure of 131/76 mmHg and no costovertebral angle tenderness.

Laboratory findings revealed serum creatinine of 0.82 mg/dL, eGFR of 99 mL/min/1.73 m<sup>2</sup>, and urinalysis revealed numerous red blood cells and mild proteinuria Table 1. There was no morphological abnormality of his kidneys in the imaging of computed tomography scan.

The kidney biopsy was performed 3 months after the onset of gross hematuria. Among 67 glomeruli sampled, there were no globally sclerotic glomeruli. All glomeruli showed diffuse and mild mesangial hypercellularity without crescent formation. There was approximately 10 % tubulointerstitial fibrosis of the cortex and no arterio- and arteriolosclerosis. Immunofluorescence revealed global mesangial staining of IgG (±), IgA (2+), IgM (±), C3 (1+), C4 (-) C1q (±) and Fibrinogen (±). Ultrastructural examination revealed electron dense deposits in the mesangium and mild podocyte foot process effacement (Fig. 2). Pathological features were consistent with IgA nephropathy and the Oxford MEST-C score was M1E0S0TOC0 [15]. His gross hematuria spontaneously resolved within 7 days without any treatment, and his microscopic hematuria and proteinuria also disappeared gradually.

## Discussion and conclusions

To our best knowledge, this is the first report showing sibling cases that developed gross hematuria and were newly diagnosed as IgA nephropathy following the SARS-CoV-2 vaccination.



**Fig. 1** Findings of the kidney biopsy specimens from patient 1. **(A)** Glomerular mesangial expansion and hypercellularity was observed (arrowheads). A cellular crescent formation was also observed. (PAS staining,  $\times 400$ ). **(B)** Glomerular mesangial deposits for IgA antisera were observed (immunofluorescence study,  $\times 400$ ). **(C)** Approximately 10–20% tubulointerstitial fibrosis of the cortex was observed (Azan staining,  $\times 100$ ). **(D)** Ultrastructural evaluation revealed the electron-dense deposits in the mesangium (arrowheads, transmission electron microscopy,  $\times 4000$ ). Abbreviation: IgA, Immunoglobulin A; PAS, Periodic acid Schiff

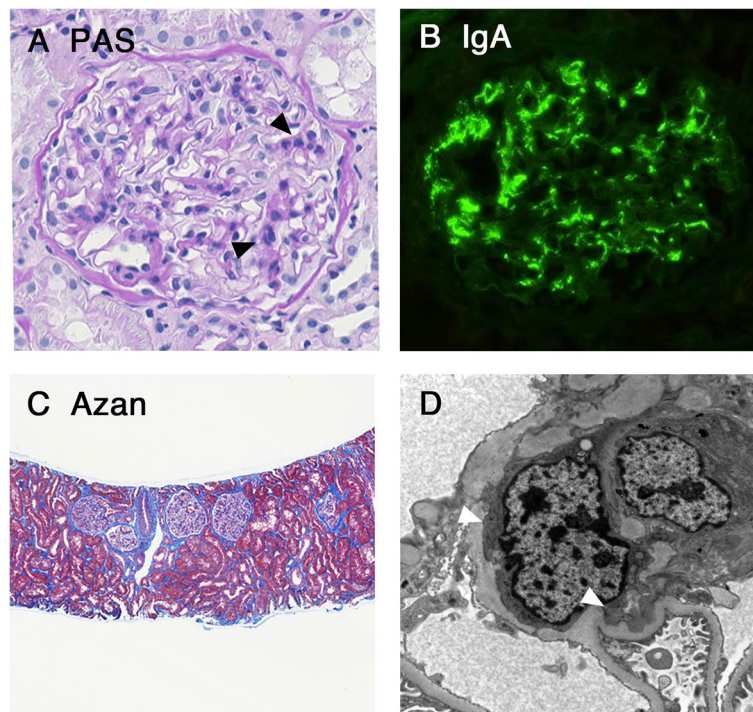
Recent reports indicate an association between gross hematuria and the SARS-CoV-2 vaccination in patients with glomerulonephritis, especially those with IgA nephropathy [6–14]. To date, vaccinations based on several mechanisms have been used clinically, although gross hematuria was only reported after receiving the mRNA vaccines [2–5]. The BNT162B2 (Pfizer) and the mRNA-1273 (Moderna) vaccines employ a purified mRNA lipid nanoparticle-encapsulated platform. This novel mRNA-based platform induces stronger antigen-specific cluster of differentiation (CD) 4+ and CD 8+ T cell responses [16]. Because the CD 4+ and CD 8+ T cells activated by vaccination produce several proinflammatory cytokines, including interferon- $\gamma$  and tumor necrosis factor- $\alpha$ , these vaccines might exacerbate immune-mediated glomerular diseases or cause *de novo* glomerulonephritis including IgA nephropathy [6].

One notable point in the present cases is that microscopic hematuria has already existed before the vaccination. In addition, the chronic histopathologic features such as tubulointerstitial damage indicate the possibility

that the immune responses to vaccination exacerbated a pre-existing undiagnosed IgA nephropathy in our cases.

Another notable point is the association between the pathogenesis of IgA nephropathy and Toll-like receptors (TLRs), which are a family of immune receptors whose activation is important for the mucosal immune responses [17]. Increased amounts of abnormally glycosylated IgA1 have been thought to be the first hit in the development of IgA nephropathy [18]. Recently, it was reported that TLR7 recognizes endogenous or exogenous single-strand RNAs and is involved in the production of abnormally glycosylated IgA1 [19]. Taken together, it is possible that the mRNA vaccination causes the production of abnormally glycosylated IgA1 via TLR signaling and is related to the exacerbation of IgA nephropathy, at least partially [20].

In conclusion, we report the first sibling cases of newly diagnosed IgA nephropathy who developed gross hematuria following the second dose of SARS-CoV-2 vaccination. These cases indicate that SARS-CoV-2 vaccination might stimulate the relapse or



**Fig. 2** Findings of the kidney biopsy specimens from patient 2. **(A)** Glomerular mesangial expansion and hypercellularity was observed (arrowheads). (PAS staining,  $\times 400$ ). **(B)** Glomerular mesangial deposits for IgA antisera were observed (immunofluorescence study,  $\times 400$ ). **(C)** Approximately 10% tubulointerstitial fibrosis of the cortex was observed (Azan staining,  $\times 100$ ). **(D)** Ultrastructural evaluation revealed the electron-dense deposits in the mesangium (arrowheads, transmission electron microscopy,  $\times 4000$ ). Abbreviation: IgA, Immunoglobulin A; PAS, Periodic acid Schiff.

trigger *de novo* IgA nephropathy. On the other hand, it remains to be unknown that gross hematuria developed in our patients was caused by chance or due to the genetic related etiology. Further studies are needed to identify how this postvaccination setting can develop and how we should manage these patients with IgA nephropathy.

#### Abbreviations

CD: cluster of differentiation; COVID-19: coronavirus disease 2019; CRP: C-reactive protein; eGFR: estimated glomerular filtration rate;  $\text{HCO}_3^-$ : bicarbonate; IgA: immunoglobulin A; LDL: low-density lipoprotein; mRNA: messenger ribonucleic acid; NAG: N-acetyl-glucosaminidase; PAS: Periodic acid Schiff; SARS-CoV-2: severe acute respiratory syndrome coronavirus 2; TLR: toll-like receptor.

#### Acknowledgments

None

#### Authors' contributions

YU, HF, YI, DN, MK and RF diagnosed and treated the patients. YU and HF drafted and HY and RF critically revised the manuscript. All authors read and approved the final manuscript.

#### Funding

None.

#### Availability of data and materials

The datasets used and/or analyzed are available from the corresponding author upon reasonable request.

#### Declarations

##### Ethics approval and consent to participate

Not applicable.

##### Consent for publication

Written informed consent was obtained from the patients and their parents for the publication of this case report. A copy of the written consent is available for review by the editor of this journal.

##### Competing interests

The authors declare that they have no competing interests.

##### Author details

<sup>1</sup>Renal Division, Department of Internal Medicine, Iwata City Hospital, 512-3 Ohkubo, Iwata, Shizuoka 438-8550, Japan. <sup>2</sup>First Department of Medicine, Hamamatsu University School of Medicine, Hamamatsu, Shizuoka, Japan.

Received: 28 February 2022 Accepted: 10 June 2022

Published online: 21 June 2022

#### References

1. Jimi H, Hashimoto G. Challenges of COVID-19 outbreak on the cruise ship Diamond Princess docked at Yokohama, Japan: a real-world story. *Glob Health Med.* 2020;2:63–5.

2. Anderson EJ, Roupael NG, Widge AT, Jackson LA, Roberts PC, Makhene M, et al. Safety and Immunogenicity of SARS-CoV-2 mRNA-1273 Vaccine in Older Adults. *New Engl J Med.* 2020;383:2427–38.
3. Polack FP, Thomas SJ, Kitchin N, Absalon J, Gurtman A, Lockhart S, et al. Safety and Efficacy of the BNT162b2 mRNA Covid-19 Vaccine. *New Engl J Med.* 2020;383:2603–15.
4. Voysey M, Clemens SAC, Madhi SA, Weckx LY, Folegatti PM, Aley PK, et al. Safety and efficacy of the ChAdOx1 nCoV-19 vaccine (AZD1222) against SARS-CoV-2: an interim analysis of four randomised controlled trials in Brazil, South Africa, and the UK. *Lancet.* 2021;397:99–111.
5. Al Kaabi N, Zhang Y, Xia S, Yang Y, Al Qahtani MM, Abdulrazzaq N, et al. Effect of 2 Inactivated SARS-CoV-2 Vaccines on Symptomatic COVID-19 Infection in Adults: A Randomized Clinical Trial. *JAMA.* 2021;326:35–45.
6. Negrea L, Rovin BH. Gross hematuria following vaccination for severe acute respiratory syndrome coronavirus 2 in 2 patients with IgA nephropathy. *Kidney Int.* 2021;99:1487.
7. Perrin P, Bassand X, Benotmane I, Bouvier N. Gross hematuria following SARS-CoV-2 vaccination in patients with IgA nephropathy. *Kidney Int.* 2021;100:466–8.
8. Tan HZ, Tan RY, Choo JCJ, Lim CC, Tan CS, Loh AHL, et al. Is COVID-19 vaccination unmasking glomerulonephritis? *Kidney Int.* 2021;100:469–71.
9. Hanna C, Herrera Hernandez LP, Bu L, Kizilbash S, Najera L, Rheault MN, et al. IgA nephropathy presenting as macroscopic hematuria in 2 pediatric patients after receiving the Pfizer COVID-19 vaccine. *Kidney Int.* 2021;100:705–6.
10. Plasse R, Nee R, Gao S, Olson S. Acute kidney injury with gross hematuria and IgA nephropathy after COVID-19 vaccination. *Kidney Int.* 2021;100:944–5.
11. Kudose S, Friedmann P, Albajrami O, D'Agati VD. Histologic correlates of gross hematuria following Moderna COVID-19 vaccine in patients with IgA nephropathy. *Kidney Int.* 2021;100:468–9.
12. Abramson M, Mon-Wei YS, Campbell KN, Chung M, Salem F. IgA Nephropathy After SARS-CoV-2 Vaccination. *Kidney Med.* 2021;3:860–3.
13. Bomback AS, Kudose S, D'Agati VD. De Novo and Relapsing Glomerular Diseases After COVID-19 Vaccination: What Do We Know So Far? *Am J Kidney Dis.* 2021;78:477–80.
14. Caza TN, Cassol CA, Messias N, Hannoudi A, Haun RS, Walker PD, et al. Glomerular Disease in Temporal Association with SARS-CoV-2 Vaccination: A Series of 29 Cases. *Kidney360.* 2021;2:1770–80.
15. Trimarchi H, Barratt J, Cattran DC, Cook HT, Coppo R, Haas M, et al. Oxford Classification of IgA nephropathy 2016: an update from the IgA Nephropathy Classification Working Group. *Kidney Int.* 2017;91:1014–21.
16. Pardi N, Hogan MJ, Naradikian MS, Parkhouse K, Cain DW, Jones L, et al. Nucleoside-modified mRNA vaccines induce potent T follicular helper and germinal center B cell responses. *J Exp Med.* 2018;215:1571–88.
17. Lind NA, Rael VE, Pestal K, Liu B, Barton GM. Regulation of the nucleic acid-sensing Toll-like receptors. *Nat Rev Immunol.* 2022;22:224–35.
18. Suzuki H, Kiryluk K, Novak J, Moldoveanu Z, Herr AB, Renfrow MB, et al. The pathophysiology of IgA nephropathy. *J Am Soc Nephrol.* 2011;22:1795–803.
19. Zheng N, Xie K, Ye H, Dong Y, Wang B, Luo N, et al. TLR7 in B cells promotes renal inflammation and Gd-IgA1 synthesis in IgA nephropathy. *JCI Insight.* 2020;5:e136965.
20. Matsuzaki K, Aoki R, Nihei Y, Suzuki H, Kihara M, Yokoo T, et al. Gross hematuria after SARS-CoV-2 vaccination: questionnaire survey in Japan. *Clin Exp Nephrol.* 2022;26:316–22.

## Publisher's Note

Springer Nature remains neutral with regard to jurisdictional claims in published maps and institutional affiliations.

Ready to submit your research? Choose BMC and benefit from:

- fast, convenient online submission
- thorough peer review by experienced researchers in your field
- rapid publication on acceptance
- support for research data, including large and complex data types
- gold Open Access which fosters wider collaboration and increased citations
- maximum visibility for your research: over 100M website views per year

At BMC, research is always in progress.

Learn more [biomedcentral.com/submissions](https://biomedcentral.com/submissions)

